



PATIENT

Matcha Li

SPECIES

Canine

BREED

Pomeranian Mix

SEX

Female Spayed

AGE

10years

WEIGHT

10.86lbs

INTERPRETED BY

Maggie Machen
 Lamy, DVM, DACVIM
 (Cardiology)

IMAGING PERFORMED BY

Jenna Walsh, CVT

HOSPITAL NAME

West Hills Animal
 Hospital

REFERRING VET

Dr. Cole

INVOICE

24559

DATE

6/2/22

PRESENTING CLINICAL SIGNS

History: Acute onset of discomfort. Inappetence and vomiting. Increased RE. Grade 3/6 heart murmur.
 -Current Medications: Cerenia, Gabapentin
 -Abnormal PE/Chem/CBC/UA Results: Na:K Ratio 26 (28-37), nRBC 6 (0-2), all other lab work WNL.

RADIOGRAPHIC FINDINGS *NOTE: Images submitted for supplemental cardiac information only.
 Mild cardiomegaly. No obvious evidence of CHF.

ELECTROCARDIOGRAPHIC FINDINGS

A six lead ECG is available at 25mm/s; 10mm/mV. The average heart rate is 80bpm (range 57-100bpm). The rhythm is sinus in origin, with a p for every QRS complex and vice versa. The P wave morphology is positive with a normal dimension. Normal PR. The QRS morphology is positive with normal dimension. MEA is normal. No ectopic beats, pauses or dysrhythmias observed.
 ECG diagnosis: Normal sinus rhythm with respiratory variation.

ECHOCARDIOGRAM FINDINGS

2D, m-mode, color flow and doppler imaging is available. Mild diffuse thickening of mitral valve leaflets with no prolapse into the left atrial lumen. Mild eccentric mitral regurgitation with mild left atrial dilation. Normal MR velocity. Normal LV diameter with adequate myocardial function. The tricuspid valve appears normal with mild tricuspid regurgitation. Normal velocity. Normal right atrial and ventricular diameter and morphology indicating no overt evidence of pulmonary arterial hypertension. The pulmonic and aortic valves are normal in morphology and mobility. Normal pulmonic and aortic outflow velocities with laminar flow. No obvious aortic or pulmonic insufficiency. No pericardial or pleural effusion noted. No obvious cardiac masses.

CARDIAC CHART

CANINE CARDIAC PARAMETERS	MR VMAX (m/s)	TR VMAX (m/s)	LA/AO (Boon method)	LA/AO (Heart Base; Swe)	FS (%)	EF (%)	EPSS (cm)
NORMAL PARAMETER	4.5-5.5	<2.7	1.3	<1.6	28-40	40-100	<0.6
PATIENT	5.4	2.2	1.5	1.3	39	73	NM
CANINE CARDIAC PARAMETERS	HR (BPM)	AV VMAX (m/s)	PV MAX (m/s)	BODY WEIGHT (kg)	LA 2D short axis Base view (cm)	LVIDd Avg; 2D and m-mode short axis (cm)	LVIDs Avg; 2D and m-mode short axis (cm)
NORMAL PARAMETER	50-100	0.7-1.7	0.7-1.6	BELOW	BELOW	BELOW	BELOW
PATIENT	NM	1.5	0.83	4.9	1.2	1.8	1.1
*Normal chamber parameters expressed as a mean value (SD)				3	1.27 (5.3)	2.46 (2.46)	1.36 (5.5)
BODY WEIGHT DEPENDENT PARAMETERS				5	1.40 (4.5)	2.74 (5.2)	1.60 (4.7)
				10	1.50 (3.8)	3.27 (3.5)	2.06 (3.1)
Adapted from June Boon, Veterinary Echocardiography, 1998				15	1.83 (2.0)	3.71 (2.4)	2.43 (2.1)
Rishniw M and Hollis NE, J Vet Intern Med 2000; 14:429-435				20	2.02 (1.9)	4.14 (2.2)	2.80 (2.0)



PATIENT

Matcha Li

SPECIES

Canine

BREED

Pomeranian Mix

SEX

Female Spayed

AGE

10years

WEIGHT

10.86lbs

INTERPRETED BY

Maggie Machen
Lamy, DVM, DACVIM
(Cardiology)

IMAGING PERFORMED BY

Jenna Walsh, CVT

HOSPITAL NAME

West Hills Animal
Hospital

REFERRING VET

Dr. Cole

INVOICE

24559

DATE

6/2/22

Hansson et al, Vet Rad and Ultrasound 2002	25	2.18 (2.4)	4.48 (2.9)	3.10 (2.5)
Bonagura et al. Echocardiography: principles of interpretation, Vet Clin North Am 15:1177, 1995	30	2.33 (3.3)	4.83 (3.9)	3.39 (3.4)
	35	2.48 (4.3)	5.17 (5.0)	3.69 (4.5)
	40	2.62 (5.2)	5.48 (6.1)	3.96 (5.4)
	50	2.88 (7.1)	6.07 (8.3)	4.46 (7.4)

INTERPRETATION OF THE FINDINGS & FURTHER RECOMMENDATIONS

Chronic degenerative valve disease causing mild mitral and tricuspid regurgitation. Lack of significant left atrial enlargement indicates the current risk for complication is low. No concurrent issues such as pulmonary hypertension are noted in this study. The ECG is unremarkable with a respiratory sinus arrhythmia.

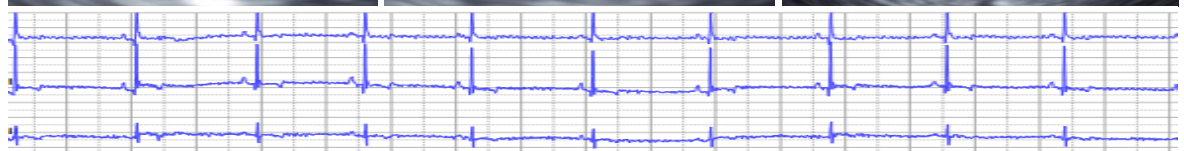
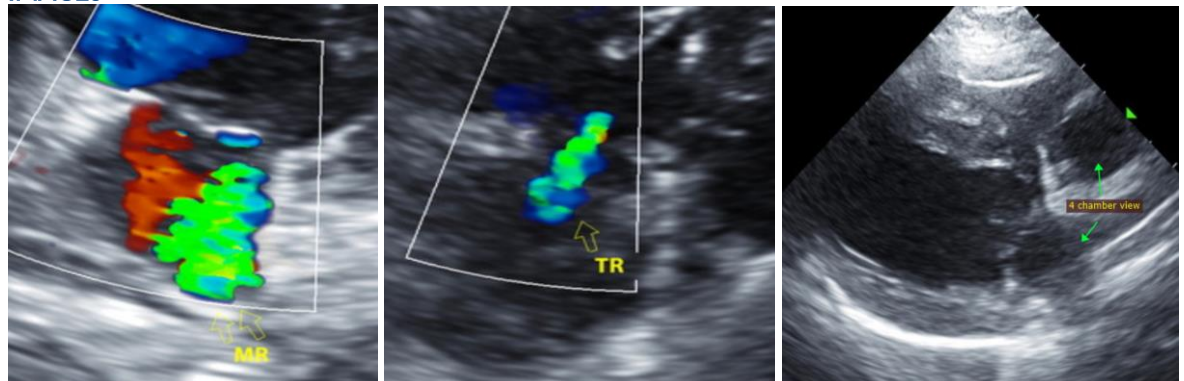
These findings would suggest current clinical issues are noncardiac in origin. Further systemic evaluation is advised.

In a dog without significant left atrial enlargement, no cardiac medications are clearly indicated. Assessment of progression in the future will help predict long term prognosis, which is highly variable at this stage (B1). Omega fatty acid supplementation and mild salt restriction may be of some long-term benefit. Monitor for development of a cough, labored breathing, exercise intolerance or collapse episodes.

Anesthetic risk is considered mild if needed. Cardiac protective drug choices (opioid/benzodiazepine premedication, propofol or alfaxalone induction, isoflurane gas) are recommended. Pre-oxygenate for 5-10 minutes prior to induction. Monitor for arrhythmias, hypotension, and hypoxia both intra and post-operatively and intervene as necessary. Mild IV fluid restriction is recommended to avoid fluid overload. Avoid heart rate stimulating drugs such as atropine unless clinically indicated.

Recommend conservative monitoring with a recheck echocardiogram in 6 months, sooner if any development of clinical signs.

IMAGES





PATIENT

Matcha Li

The information and recommendations provided are based on the images presented by the referring veterinarian. No evaluation can be communicated regarding pathology that was not visible in the image/video clips provided.

SPECIES

Canine

Thank you for this referral. This report was generated using transcription software, and minor dictation errors may be present. If the clinical or image interpretation does not parallel your findings or if I can be of any further assistance, please contact me.

BREED

Pomeranian Mix

Maggie Machen Lamy, DVM
Diplomate of the American College of Veterinary Internal Medicine (Cardiology)
info@sonopath.com

SEX

Female Spayed

AGE

10years

WEIGHT

10.86lbs

INTERPRETED BY

Maggie Machen
Lamy, DVM, DACVIM
(Cardiology)

**IMAGING
PERFORMED BY**

Jenna Walsh, CVT

HOSPITAL NAME

West Hills Animal
Hospital

REFERRING VET

Dr. Cole

INVOICE

24559

DATE

6/2/22